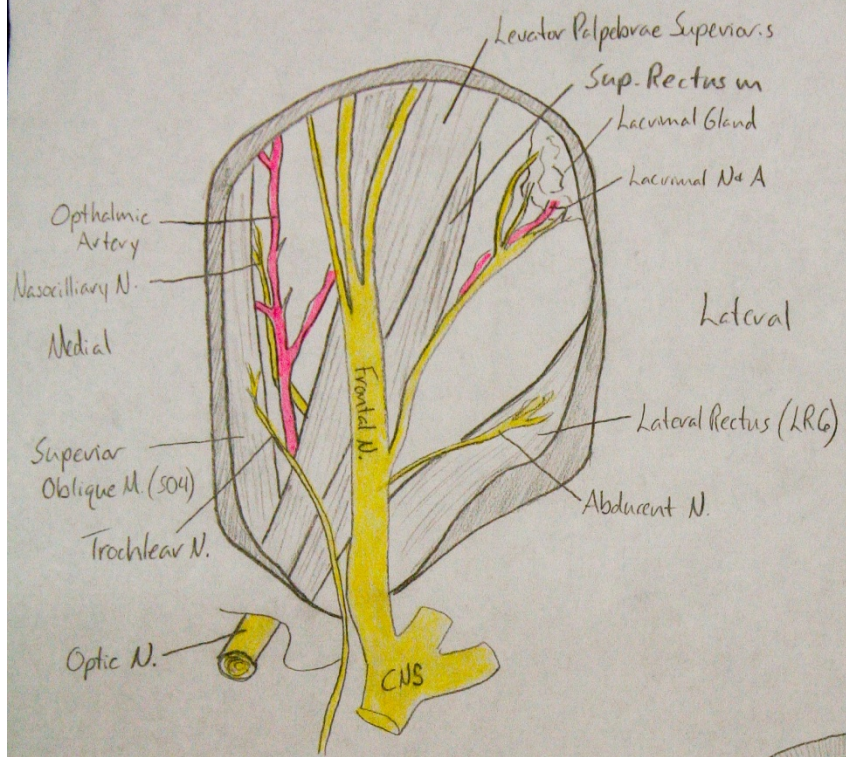


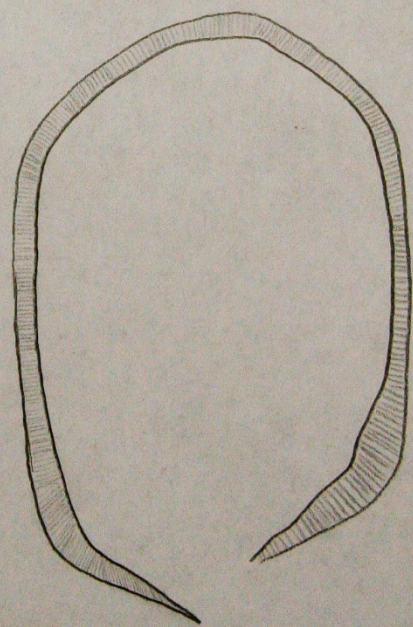
GROSS ANATOMY III LAB FINAL

Mike Murray – for chiropracticstudent.vonviceroy.com

Lab XIII - Orbit



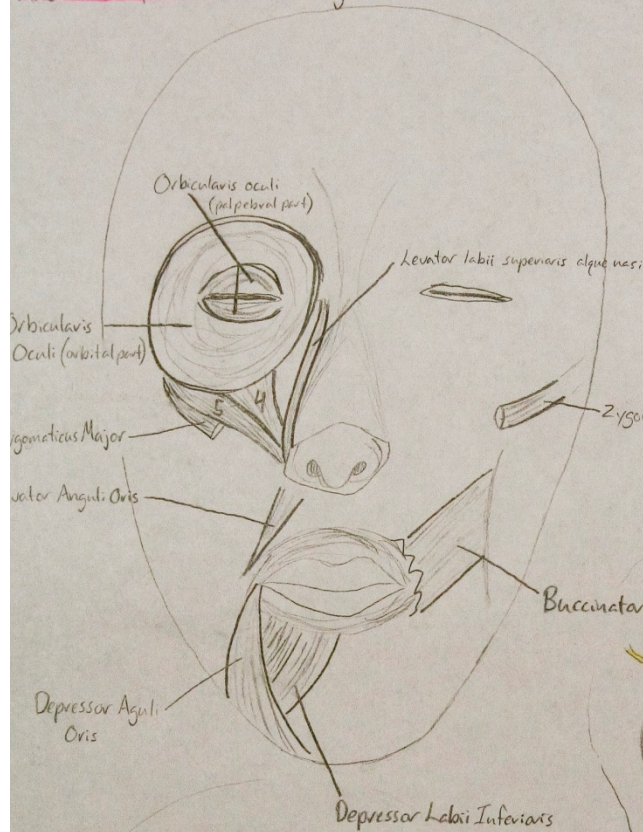
- * **Medial Rectus** is below Sup. Ob.
- * **Inf. Rectus** lies below Optic N.
- * **Oculomotor N.** can be easily found by reflecting Levator Palpebrae + viewing it inserting into the underside muscle belly
- * **Inferior Oblique m.** can be viewed from anterior through lower eye-lid



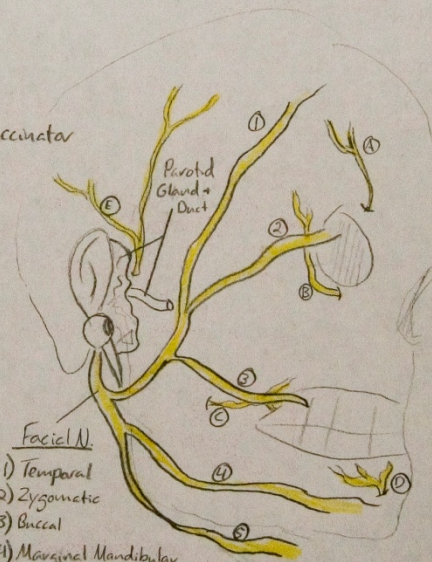
Lab XII Face + Parotid Region

4) Levator labii superioris

5) Zygomaticus Minor



find Canalis facialis!

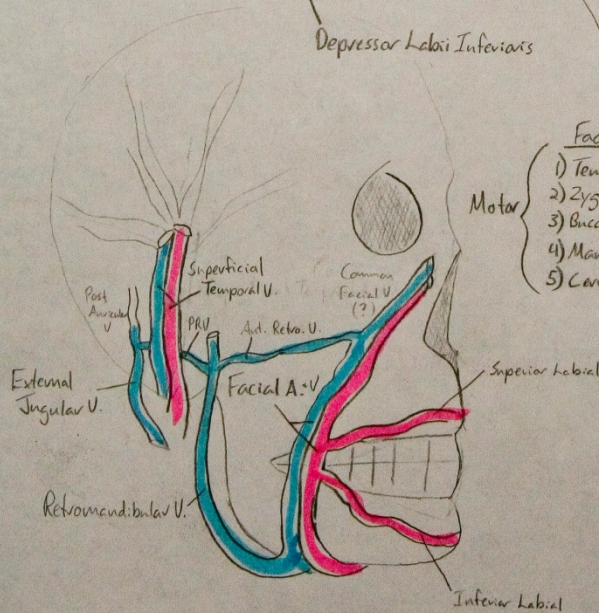


Facial N.

- Motor
- 1) Temporal
 - 2) Zygomatic
 - 3) Buccal
 - 4) Marginal Mandibular
 - 5) Cervical

Trigeminal N.

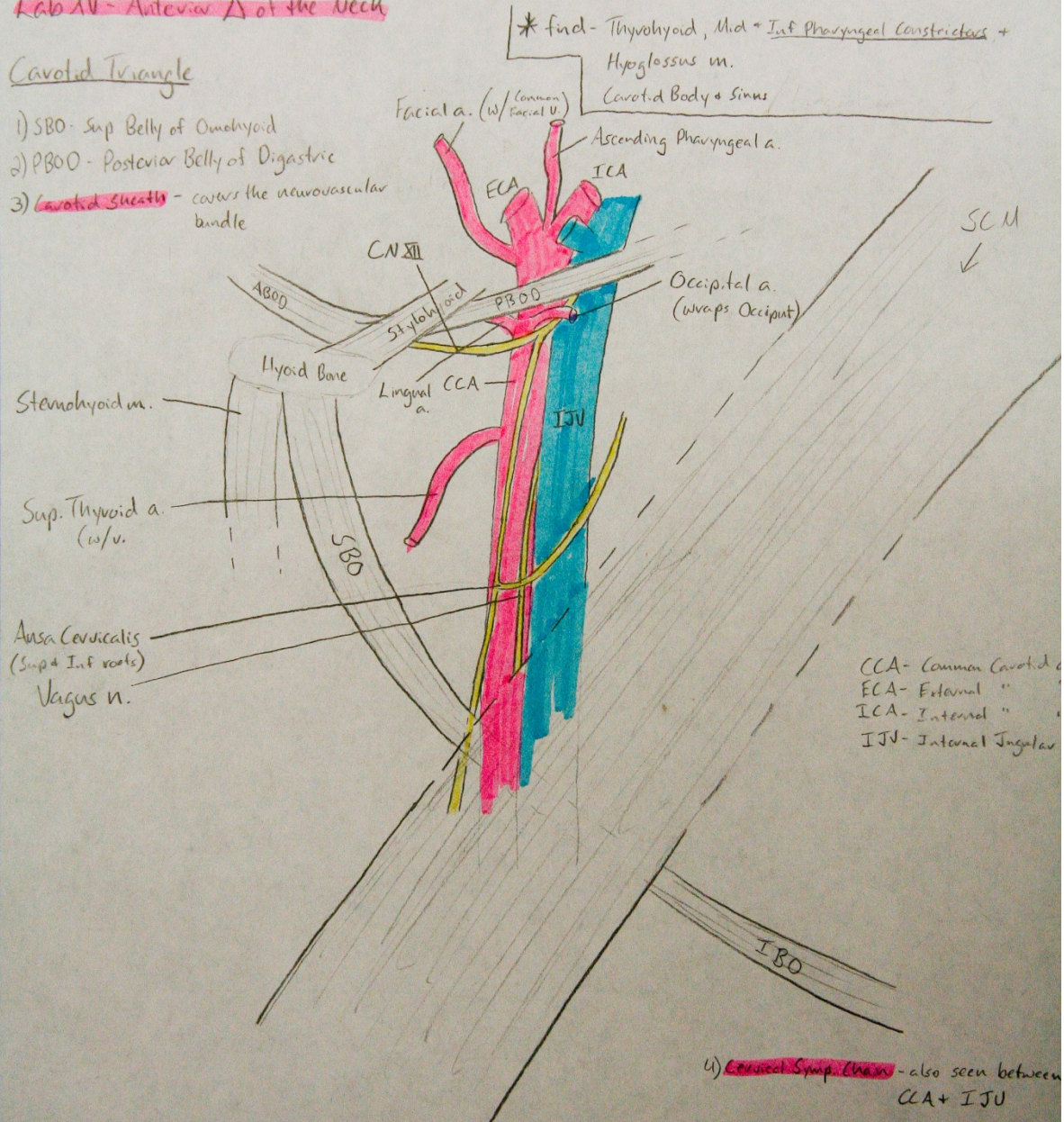
- A) Supraorbital
- B) Infraorbital
- C) Buccal
- D) Mental
- E) Auriculotemporal



Lab XV - Anterior Δ of the Neck

Carotid Triangle

- 1) SBO - Sup Belly of Omohyoid
- 2) PBOO - Posterior Belly of Digastric
- 3) Carotid Sheath - covers the neurovascular bundle



* find - Thyrohyoid, Mid = Inf Pharyngeal Constrictors, + Hyoglossus m. Carotid Body + Sinus

CCA - Common Carotid
 ECA - External "
 ICA - Internal "
 IJV - Internal Jugular

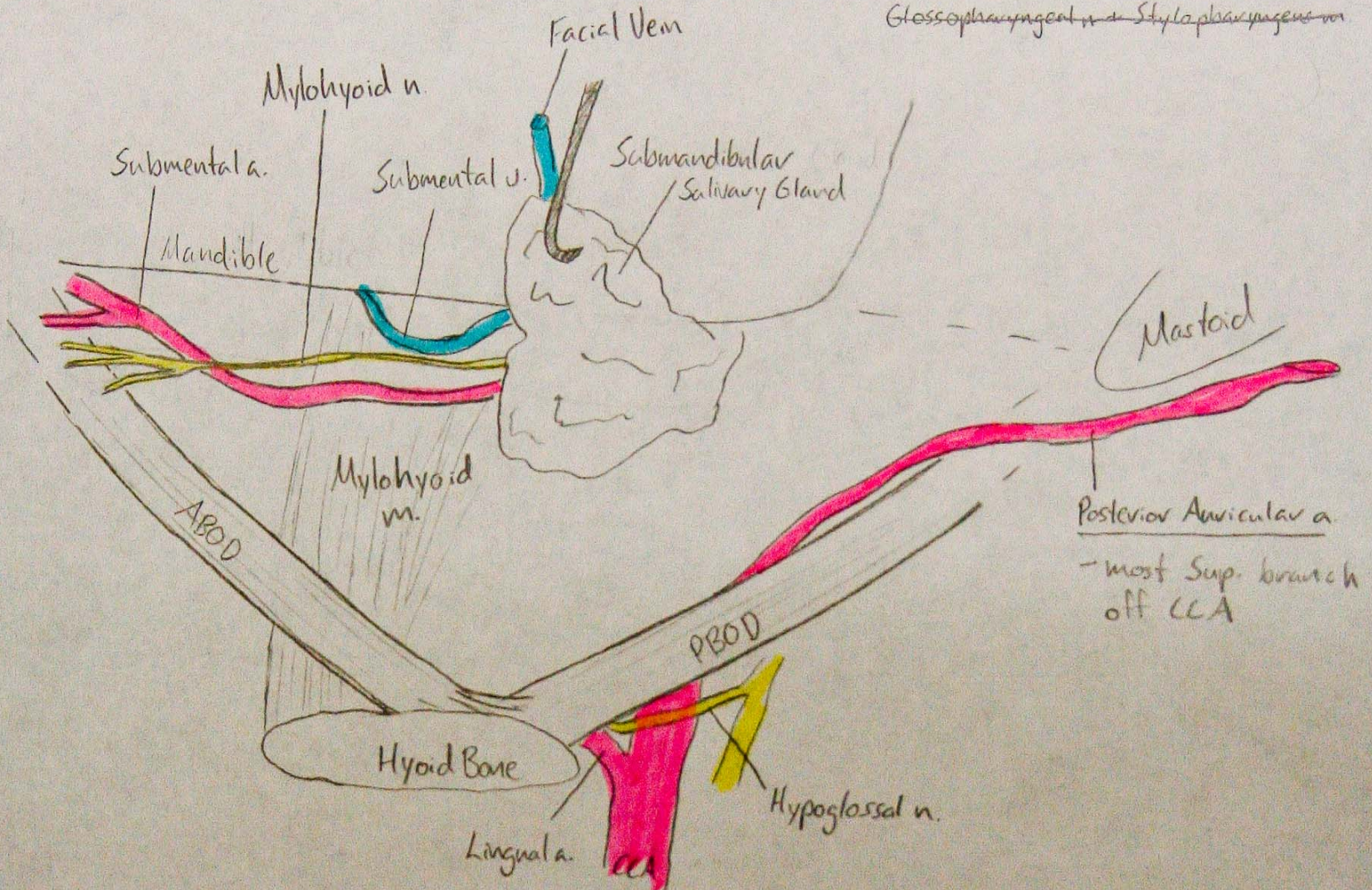
4) Cervical Symp. Chain - also seen between CCA + IJV

* Sup. Laryngeal n. - branch off vagus w/ 2 branches:
 Int + Ext Laryngeal
 ↓
 supplies Cricothyroid + Inf Pharyngeal Constrictor

LAB XIII - Anterior Δ of the Neck (cont'd)

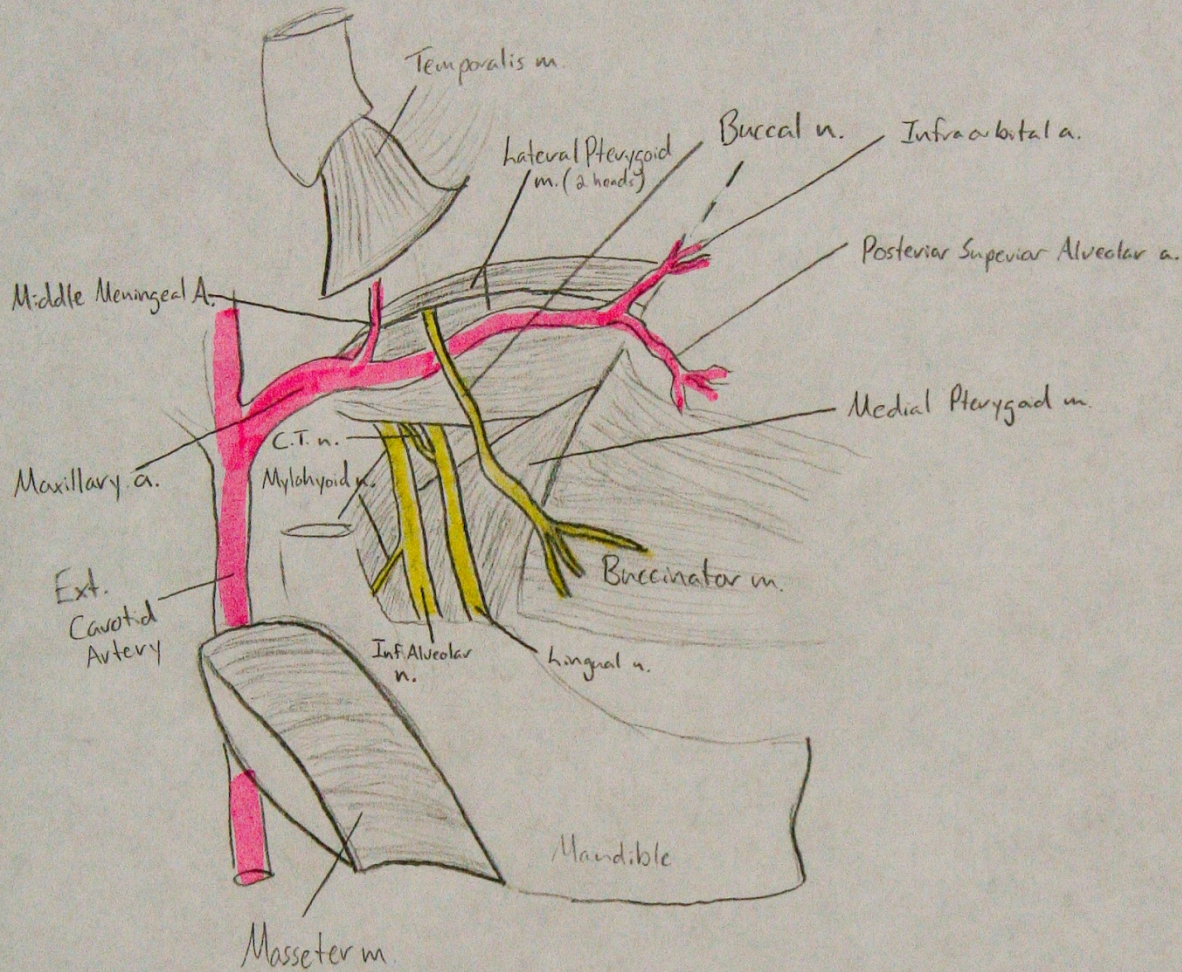
Digastric Triangle

* Find - Geniohyoid m., Hyoglossus m.,
Lingual n., Submandibular Ganglion + Duct
Glossopharyngeal n. + Stylopharyngeus m.



Lab XVII - Infratemporal Fossa

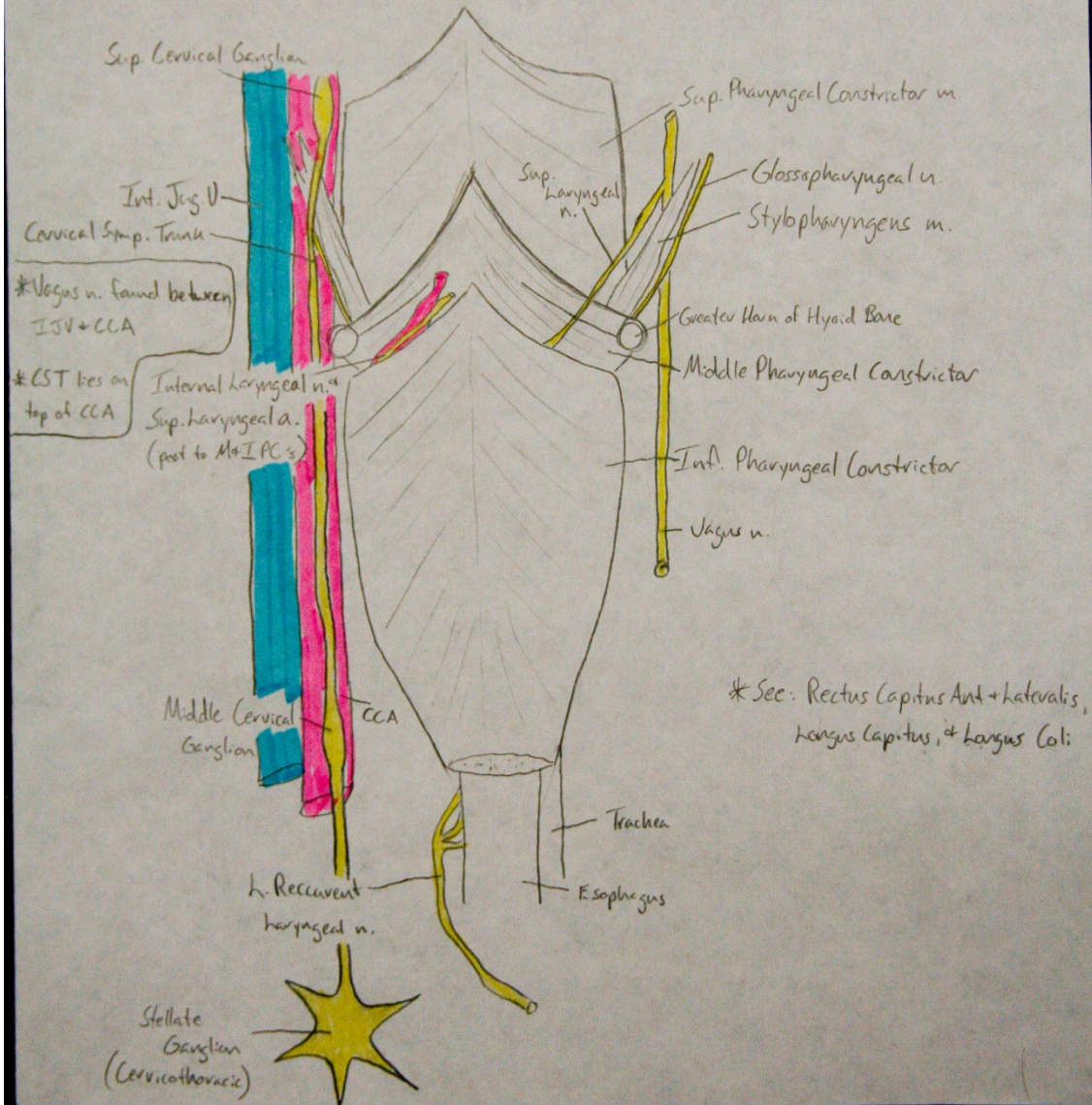
i) Auriculo Temporal n - wraps around Middle Meningeal Branch



C.T. n. - chorda tympani n. → enters the lingual n. @ an acute angle
Articular Disc - seen @ TMJ

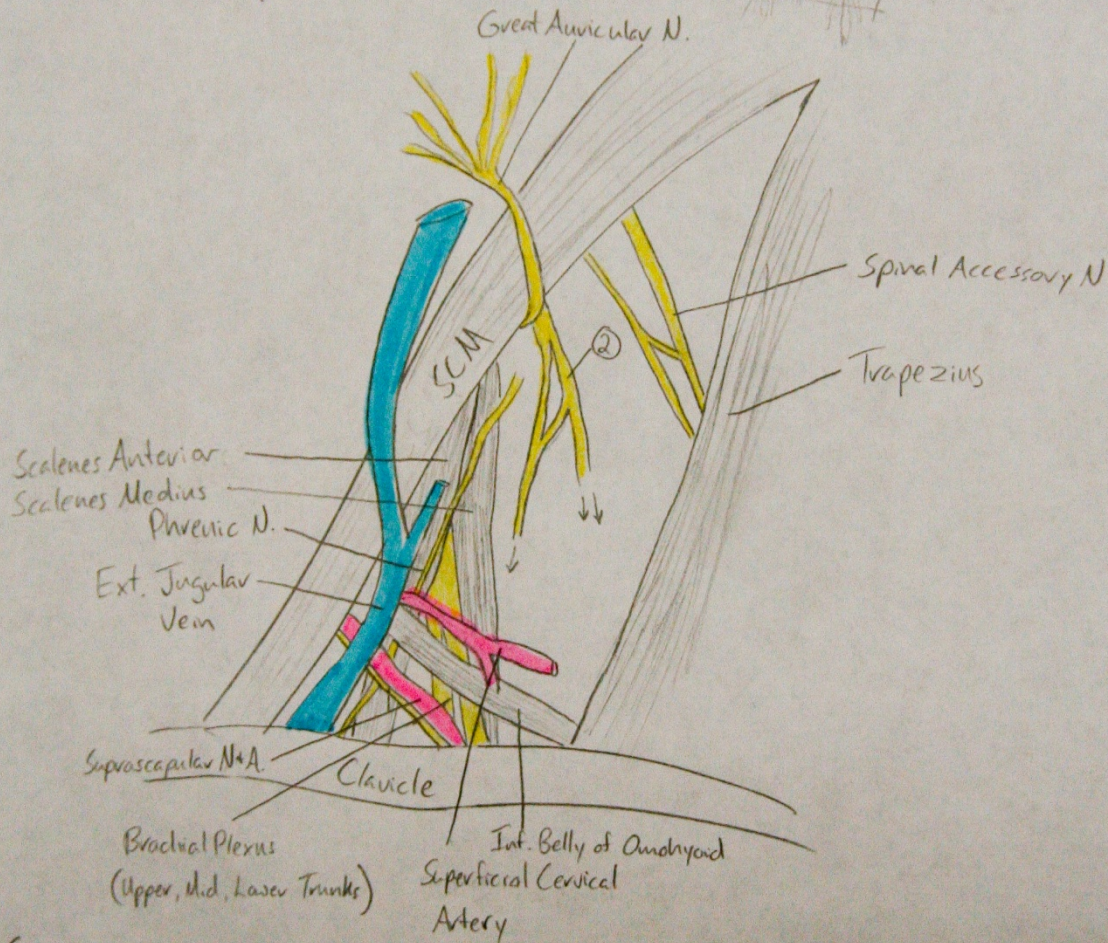
Lab XIX - Reflection of the Head

D) Buccopharyngeal Fascia - covers posterior surface of pharyngeal constrictors



Lab XIV - Posterior Δ of the Neck

- 1) Platysma - muscle sheath covering the neck
- 2) Supraclavicular Ns - piercing Platysma, running towards clavicle
- 3) Long Thoracic N. - w/ Scalenus Medius, emerging from lower part



See:

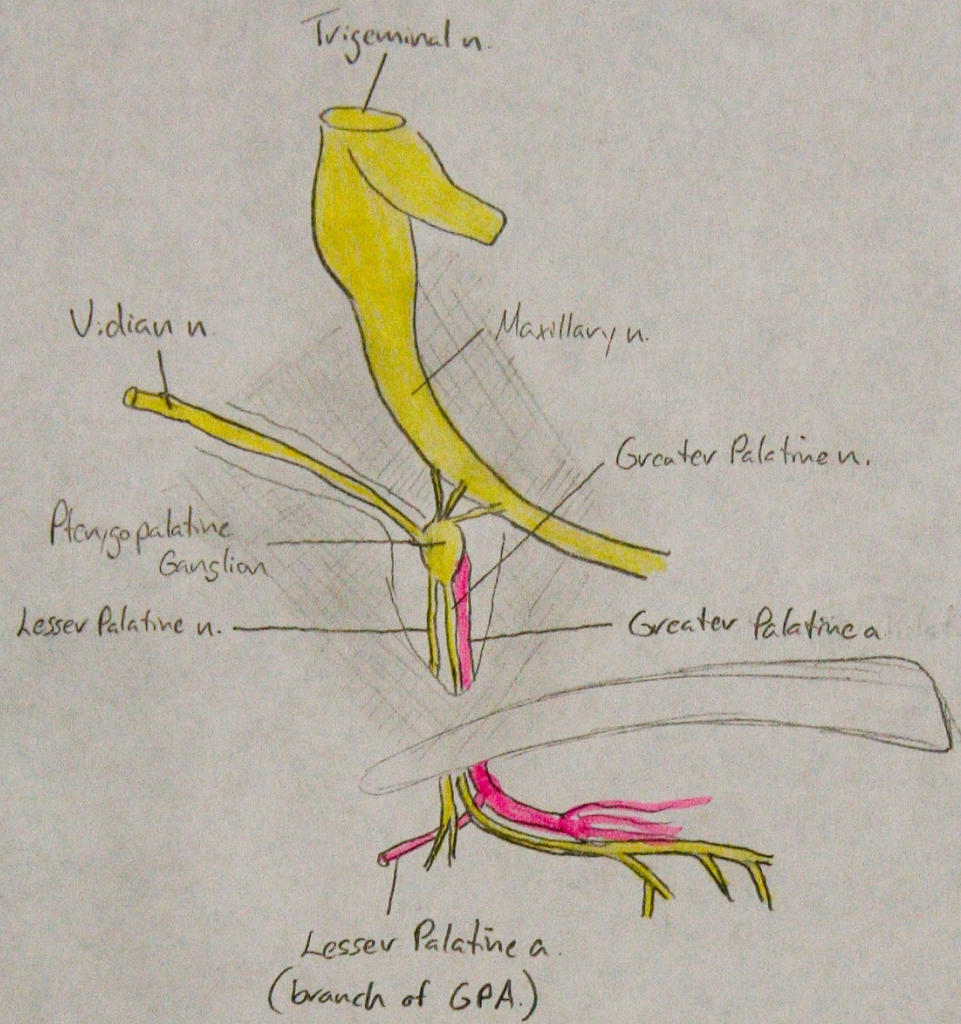
Scalenus Posterior, Subclavian V & A.

Thyrocerical Trunk

- giving rise to Sup. Cervical A. + Suprascapular A.

LAB XXI - Nasal Nerves + Vessels

* see: all other easy structures!



* Spheno ethmoidal recess
- sup. to sup. nasal conchae